



PATIENT

Lil Boy Deluca

PRESENTING CLINICAL SIGNS

Dental disease

SPECIES

Feline

Abnormal PE/Chem/CBC/UA Results: Dental calculus Heart murmur grade 2/6

BREED

DSH

SEX

MN

AGE

10

WEIGHT

11.9

ULTRASONOGRAPHIC EXAMINATION OF THE HEART

FELINE CARDIAC PARAMETERS	BODY WEIGHT	HR (BPM)	IVSd (cm)	LVIDd (cm)	LVWd (cm)	FS (%)	EF (%)
NORMAL PARAMETER	-----	150-240	0.3-0.6	1.0-2.1	0.25-0.6	35-67	80-100
PATIENT	11.9	NM	0.49	1.5	0.51	50	82
FELINE CARDIAC PARAMETERS	LA/AO M-Mode	LA/AO HEART BASE (Sisson)	LAD LA MAX 4 Chamber		LVOT VEL. (m/s)	RVOT VEL. (m/s)	IVRT (m/)
NORMAL PARAMETER	<1.5	1.6	0.7-1.7		<1.6	<1.3	40-60
PATIENT	--	1.4	1.3		1.0	1.0	NM

Sisson D et al. JVIM 1991; 5: 232, Jacobs et al. Am J Vet Res 1985; 46:1705

Cardiac Presentation

The echocardiogram in this patient demonstrated normal left atrial size based on 3 separate LA measurements. The cranial and caudal mitral valve leaflets presented normal linear structure and kinetics. No overt MR present on Doppler. The left ventricle presented normal thicknesses with linear contour and was not dilated nor restricted. The myocardium presented normal echogenicity without subjective evidence of significant fibrotic or ischemic disease. The contractility of the ventricular walls was adequate and in normal range for this patient evidenced by the fractional shortening measurement and subjective evaluation of the different regions and angles of the myocardium. The left ventricular outflow tract demonstrated normal laminar flow and subjective structural integrity. Normal measured LVOT velocity was present. The right atrium and auricle revealed normal size, structure and content. No evidence of masses was noted or chamber overload. Tricuspid valvular assessment demonstrated adequate linear morphology and kinetics. The right ventricle was of normal size (1/3 diameter of LV), chordae structure, myocardial echogenicity and thickness. Pulmonic tract assessment revealed normal valve structure, laminar flow, and diameter (approx.1:1 pa/ao ratio). Normal measured RVOT velocity was present. No visible pericardial or free pleura fluid was noted or extra cardiac pathology in the visible planes. The cranial mediastinum and pericardial regions were free of masses in the visible window.

ULTRASONOGRAPHIC FINDINGS

Primary

INTERPRETED BY

R. McKenzie Daniel, DVM, DABVP (Canine and Feline)

IMAGING PERFORMED BY

Dr Sharkawy

HOSPITAL NAME

Kew Gardens Animal Hospital

REFERRING VET

Dr Nader

INVOICE
24429

DATE
04/09/2026



PATIENT

- Normal cardiac structure/function

Lil Boy Deluca

INTERPRETATION OF THE FINDINGS & FURTHER RECOMMENDATIONS

SPECIES

No evidence of clinical issues such as HCM criteria, left/right chamber enlargement, LV systolic dysfunction, or significant valvular insufficiencies. The definitive cause of the murmur was not identified. Assuming no volume changes such as dehydration or anemia, a benign flow murmur is probable. A small non-visualized flow abnormality is not excluded. Regardless of classification, the hemodynamic effects of the murmur are low. Monitoring of the heart murmur is recommended without indication for cardiac medications. Recheck echocardiogram is recommended in 6-12 months, sooner if murmur intensity increases or clinical signs arise.

Feline

BREED

DSH

SEX

No anesthetic contraindications. Suggested anesthetic protocol may include opioid or Benzodiazepine pre-med, induction with Propofol or Alfaxalone, and appropriate gas anesthesia with avoidance of alpha 2 agonists.

MN

AGE

10

WEIGHT

11.9

INTERPRETED BY

R. McKenzie Daniel,
DVM, DABVP
(Canine and Feline)

IMAGING PERFORMED BY

Dr Sharkawy

HOSPITAL NAME

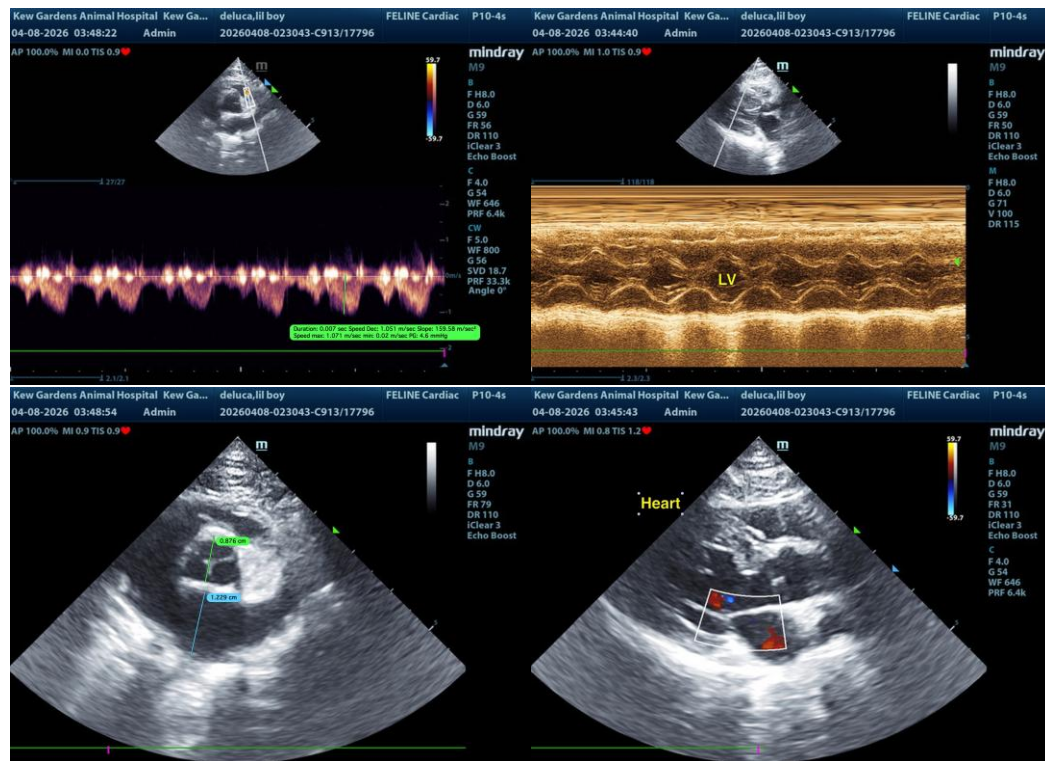
Kew Gardens Animal
Hospital

REFERRING VET

Dr Nader

INVOICE
24429

DATE
04/09/2026



The information and recommendations provided are based on the images presented by the referring veterinarian/sonographer. No evaluation can be communicated regarding pathology that was not visible in the image/video clips provided.

Thank you for this referral. If the clinical or image interpretation does not parallel your findings or if I



PATIENT

can be of any further assistance, please contact me.

Lil Boy Deluca

R. McKenzie Daniel, DVM, DABVP (Canine/Feline Practice)
info@sonopath.com

SPECIES

Feline

BREED

DSH

SEX

MN

AGE

10

WEIGHT

11.9

INTERPRETED BY

R. McKenzie Daniel,
DVM, DABVP
(Canine and Feline)

IMAGING PERFORMED BY

Dr Sharkawy

HOSPITAL NAME

Kew Gardens Animal
Hospital

REFERRING VET

Dr Nader

INVOICE 24429

DATE
04/09/2026